

PATIENT

Laney NJSHR

PRESENTING CLINICAL SIGNS

History: Anesthetic reaction during spay on 3/27. Revived with CPR. No HM or arrhythmia on exam
Current meds PLYte Metacam Convenia

SPECIES

Canine

BREED

Chihuahua

SEX

FS

AGE

5 years

WEIGHT

8.6 lbs

INTERPRETED BY

Maggie Machen Lamy,
DVM, DACVIM
(Cardiology)

IMAGING PERFORMED BY

HOLTER MONITOR FINDINGS AND RHYTHM ASSESSMENT

Time analyzed	23:13h
Mean heart rate	92 bpm
Maximum heart rate	189bpm
Minimum heart rate	47bpm
VPCs	0
APCs	0

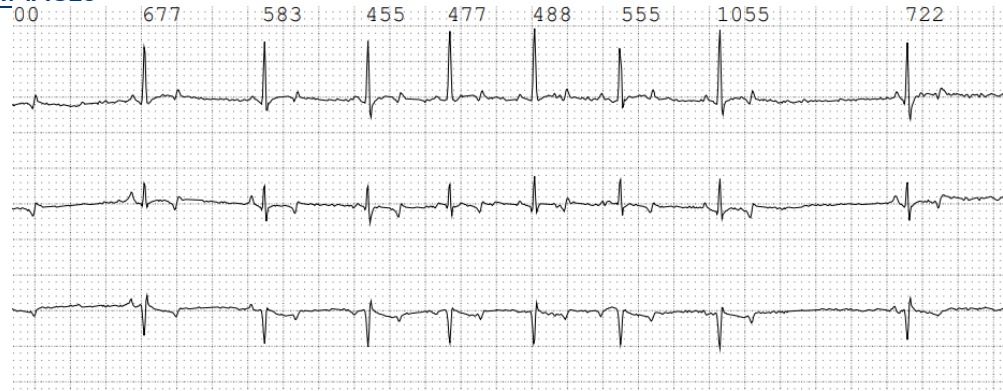
Interpretation: Underlying normal sinus rhythm with appropriate rate variation. Max heart rate appears sinus and no dysrhythmias are observed.

Rhythm diagnosis: Sinus rhythm with no dysrhythmias observed.

RECOMMENDATIONS

Normal recording. An anesthetic event is unlikely cardiac in origin, without evidence of arrhythmias, a heart murmur or associated clinical signs. A drug reaction or other issue is suspected.

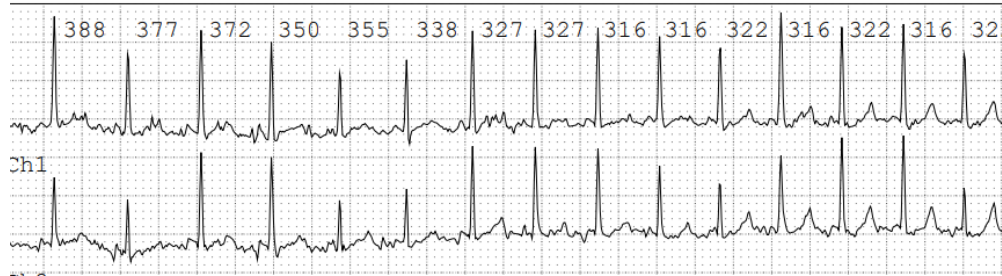
IMAGES



HOSPITAL NAME

Rockaway AH

10:21:57am-2 Max. heart rate H



REFERRING VET

Dr. Maniar

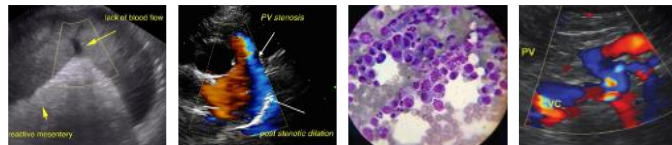
INVOICE

29940

DATE

3/29/23

The information and recommendations provided are based on the images presented by the referring veterinarian. No evaluation can be communicated regarding pathology that was not visible in the image/video clips provided.



PATIENT

Laney NJSHR

Thank you for this referral. If the clinical or image interpretation does not parallel your findings or if I can be of any further assistance please contact me.

SPECIES

Canine

Maggie Machen Lamy, DVM

Diplomate of the American College of Veterinary Internal Medicine (Cardiology)

info@sonopath.com

BREED

Chihuahua

SEX

FS

AGE

5 years

WEIGHT

8.6 lbs

INTERPRETED BY

Maggie Machen Lamy,
DVM, DACVIM
(Cardiology)

**IMAGING
PERFORMED BY**

HOSPITAL NAME

Rockaway AH

REFERRING VET

Dr. Maniar

INVOICE

29940

DATE

3/29/23